

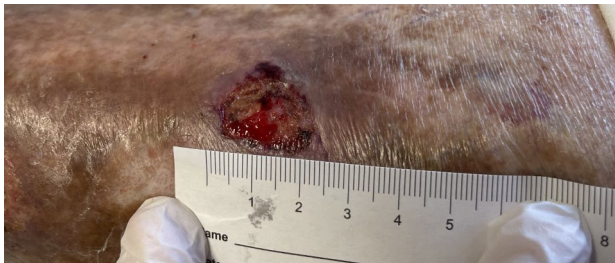Case Study

Zenith™ Amniotic Membrane

Case presented by Jacob Fassman, DPM; Podiatrist;
Colorado Foot and Ankle; Colorado Springs, CO

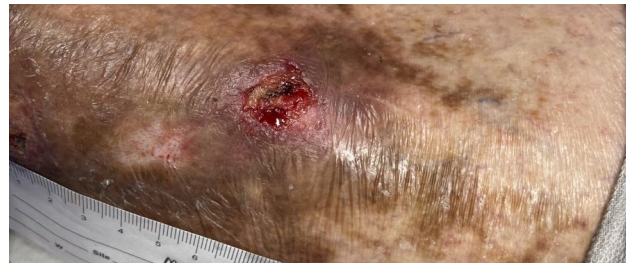77 year old female with H/O left leg venous insufficiency and previous venous ulcerations. Left leg wound started with trauma from car door one month prior. Applied collagenase ointment daily for four weeks without significant improvement.

Location: **Left leg**
Wound type: **Venous ulcer**
Weeks to resolution: **8**
Total number of Zenith applications: **7**



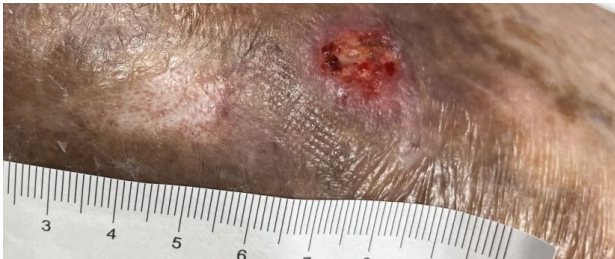Size: **2 x 1.5 x 0.1 cm**

WEEK 1 Debridement with application of 2 x 3 cm Zenith



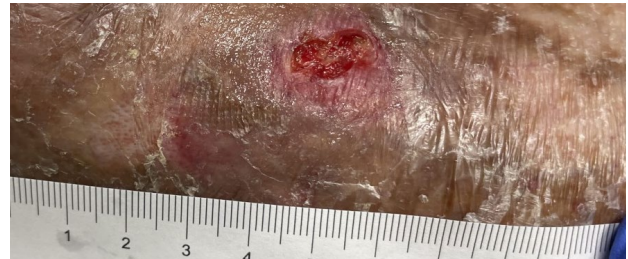Size: **1.6 x 1.3 x 0.1 cm** | Volume reduced: **31%**

WEEK 2 After debridement, application of 2 x 3 cm Zenith



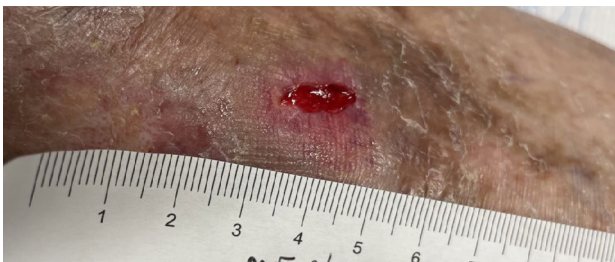Size: **1.3 x 0.9 x 0.1 cm** | Volume reduced: **44%**

WEEK 3 After debridement, application of 2 x 3 cm Zenith



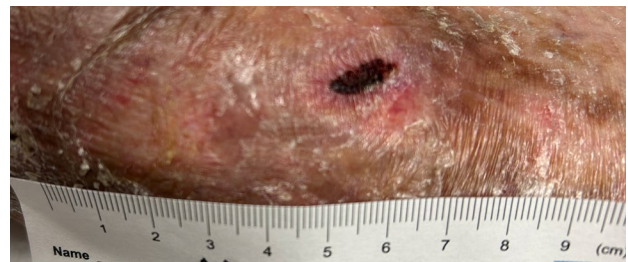
Size: **1.2 x 0.5 x 0.1 cm** | Volume reduced: **52%**

WEEK 5 After additional Zenith in week 4, patient is improving; fifth 2 x 3 cm Zenith applied after debridement



Size: **1.3 x 0.3 x 0.1 cm** | Volume reduced: **35%**

WEEK 6 After debridement, application of 2 x 3 cm Zenith



Size: **Wound resolved**

WEEK 8 After additional Zenith application in week 7, wound healed

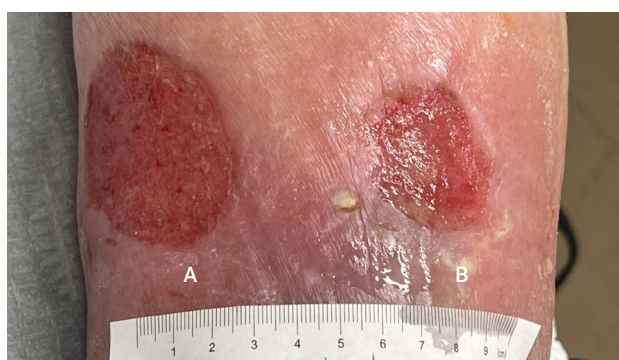
Case Study

Impax™ Dual Layer Membrane

Case presented by Jacob Fassman, DPM; Podiatrist;
Colorado Foot and Ankle; Colorado Springs, CO

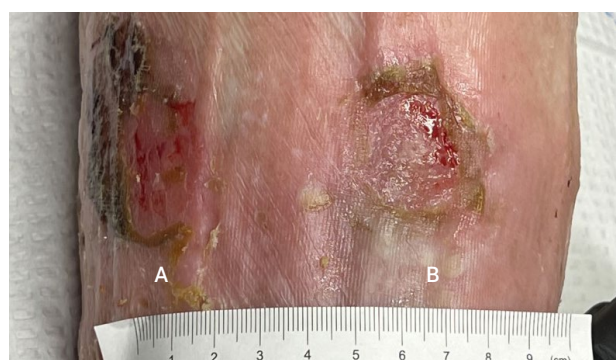
A 74 YEAR OLD MALE with a history of diabetes, GERD, COPD, hypertension, atrial fibrillation, and hypercholesterolemia presented for an urgent visit due to left lower extremity ulcerations. The patient has a history of venous insufficiency and venous ulcerations.

Location: **Left leg**
Wound type: **Venous ulcer**
Weeks to resolution: **4**
Total number of Impax applications: **3**



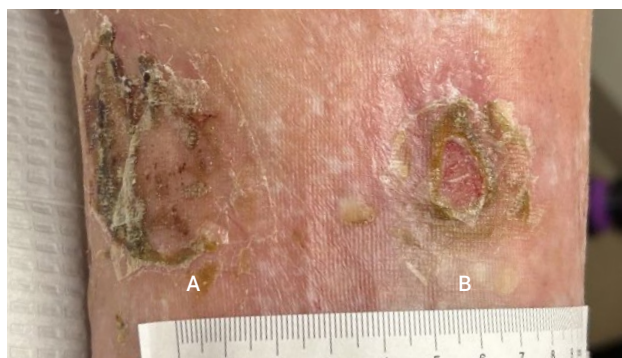
Sizes: (A) **6 x 4.5 x 0.1 cm** | (B) **2.5 x 3 x 0.1 cm**

INITIAL VISIT Incision, draining, and debridement, with Impax to be applied at next follow-up



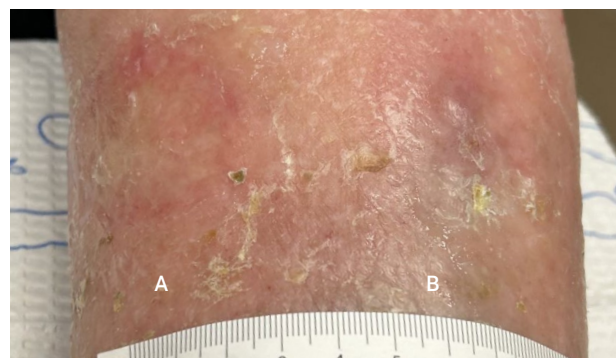
Sizes: (A) **6 x 4.5 x 0.1 cm** | (B) **2.5 x 3 x 0.1 cm**

WEEK 1 After sharp excisional debridement, application of 4 x 8 cm Impax



Sizes: (A) **3 x 1.8 x 0.1 cm** | Volume reduced: **80%**
(B) **2.5 x 2 x 0.1 cm** | Volume reduced: **33.3%**

WEEK 2 Patient tolerating Impax well; a second 4 x 8 cm Impax is applied



Sizes: (A) **Wound resolved**
(B) **1.5 x 1 x 0.1 cm** | Volume reduced: **70%**

WEEK 3 Patient is improving; a third 4 x 4 cm Impax is applied, after which wounds are completely healed at fourth week follow-up

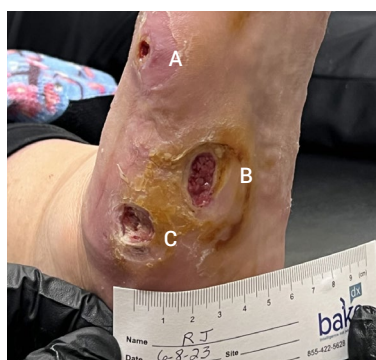
Case Study

Impax™ Dual-Layer Amniotic Graft

Case presented by Jacob Fassman, DPM; Podiatrist;
Colorado Foot and Ankle; Colorado Springs, CO

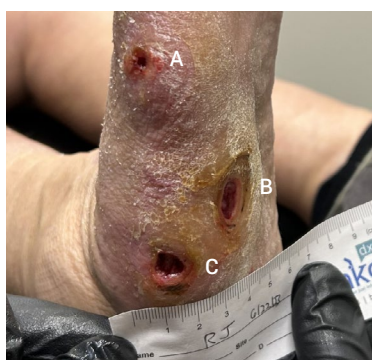A 70 YEAR OLD FEMALE with osteoarthritis, hypertension, and neuropathy presented with three pressure/ neuropathic ulcers on right foot that had been present for four months with a history of infection. Treated at wound clinic without significant improvement. Referred to vascular specialist who determined adequate blood flow for healing and no significant PAD.

Location: **Right foot**
Wound type: **Pressure/neuropathic ulcer**
Weeks to resolution: **13**
Total number of Impax applications: **6**



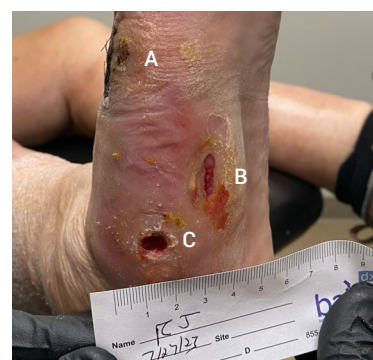(A) 0.9 x 0.8 x 0.3 cm
(B) 4.6 x 3.3 x 0.2 cm
(C) 2 x 1.2 x 0.3 cm

INITIAL VISIT Post-debridement applied 2 x 2 cm Impax to all wounds



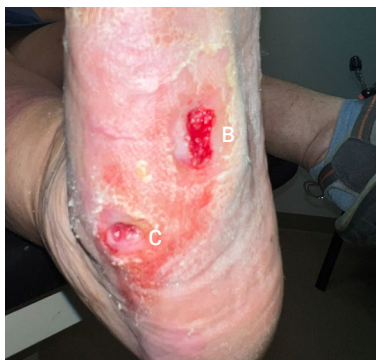(A) 0.2 x 0.3 x 0.2cm | Reduced 94%
(B) 1.1 x 0.5 x 0.2 cm | Reduced 96%
(C) 0.6 x 0.8 x 0.3 cm | Reduced 80%

2-WEEK VISIT Post-debridement applied 2 x 2 cm Impax to all wounds



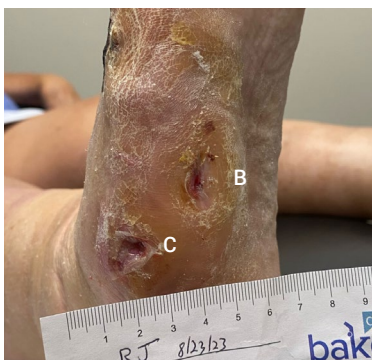
(A) Wound resolved
(B) 1.8 x 0.4 x 0.1 cm | Reduced 35%
(C) 0.3 x 0.6 x 0.3 cm | Reduced 63%

6-WEEK VISIT After surgery to remove infected bone and resolution of infection; post-debridement applied 2 x 2 cm Impax to all wounds



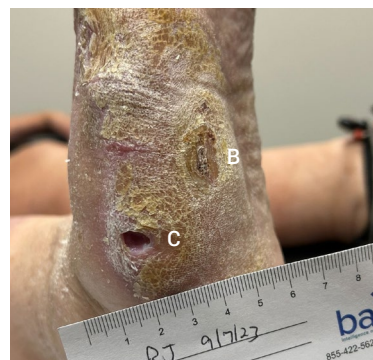
(B) 1.1 x 0.4 x 0.1 cm | Reduced 39%
(C) 0.3 x 0.4 x 0.2 cm | Reduced 56%

8-WEEK VISIT Post-debridement applied 2 x 2 cm Impax to all wounds



(B) 0.5 x 0.1 x 0.1 cm | Reduced 89%
(C) 0.6 x 1 x 0.2 cm | Increased 400%

10-WEEK VISIT Post-debridement applied 2 x 2 cm Impax to all wounds



(B) Wound resolved
(C) 0.4 x 0.6 x 0.3 cm | Reduced 40%

12-WEEK VISIT Post-debridement applied 2 x 2 cm Impax to wound; all wounds resolved at week 13